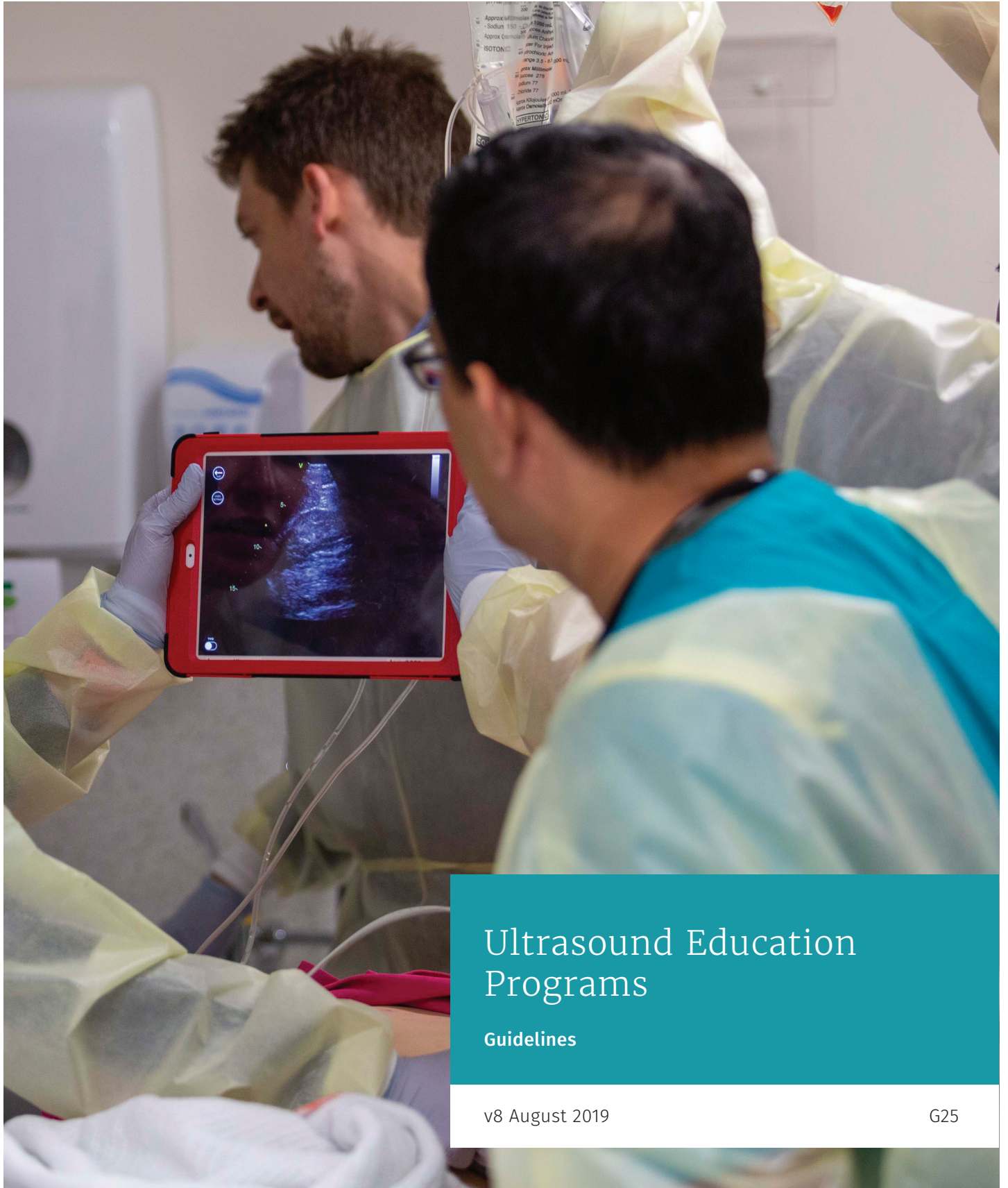


Australasian College for Emergency Medicine

acem.org.au



Ultrasound Education Programs

Guidelines

v8 August 2019

G25

Document Review

Timeframe for review:	every five (5) years, or earlier if required.
Document authorisation:	Council of Education
Document implementation:	ED Ultrasound Committee
Document maintenance:	Department of Policy and Strategic Partnerships

Revision History

Version	Date	Pages revised / Brief Explanation of Revision
V1	July 2000	Approved by Council
V2	Sept 2001	Approved by Council
V3	July 2006	Approved by Council
V4	July 2012	Approved by Council
V5	Nov 2013	Approved by Council
V6	Mar 2016	Approved by Council of Advocacy, Practice and Partnerships 'Workshop' has replaced the use of 'course' throughout the policy. "Purpose and Scope" combined under one heading. Items previously included under 'Scope' now included under a new heading – 'Objectives of Ultrasound Workshop'. Minor changes made under 'Resources': The term 'workshop faculty' is used in place of 'Course faculty'. A record of workshop hours is now required for CPD points rather than CME points.
V7	Aug 17	Approved by Council of Advocacy, Practice and Partnerships Clarified models to be used for scanning [3(d)]; provided for the use of ultrasound
V8	Aug 19	Approved by Council of Education

Supporting documents

P733 Policy on Credentialing for Emergency Medicine Ultrasonography

1. Purpose

This document describes the minimum criteria appropriate for emergency medicine ultrasound education programs in Australasia.

This document should be read in conjunction with [P733 Policy on Credentialing for Emergency Medicine Ultrasonography](#), which specifies appropriate criteria for credentialing of individuals.

2. Objectives of ultrasound education programs

On completion of an ultrasound education program, participants will demonstrate knowledge and understanding of:

- (a) the theory of ultrasound;
- (b) practical applications and limitations of focused emergency ultrasound;
- (c) the credentialing process for specific emergency ultrasound indications;
- (d) the need for ongoing emergency ultrasound CPD to maintain skills; and
- (e) be able to perform and interpret emergency ultrasound scans.

3. Education program structure

An education program may consist of a combination of online modules, lectures and face-to-face workshops.

Emergency ultrasound workshops require a significant commitment of personnel, equipment and advanced planning. Basic components necessary include:

Education

- An education program syllabus as well as a list of recommended texts and other references.
- A workshop site of sufficient area to accommodate both lectures and the practical sessions.
- Evidence of attendance including an appropriate certificate of completion.
- A pre-and post-test to demonstrate acquisition of ultrasound proficiency and interpretation.

Faculty

- a medical specialist with appropriate and extensive clinical experience and qualifications including experience in the use of ultrasound in the peri-arrest setting.
- Practitioners with significant practical experience in the application of emergency ultrasound.
- registered sonographers who may assist with teaching of the skills related to the fundamentals of ultrasound, image acquisition and interpretation.

Equipment

- appropriate ultrasound machines and transducers with a ratio of no less than 1 machine for a maximum of 5 students.

4. Practical ultrasound sessions

It is essential that practical ultrasound sessions include:

- (a) Demonstration of correct application protocol for emergency indication.
- (b) Minimum time – two hours each for abdominal aortic aneurysm, EFAST and ultrasound guided procedures. Four hours for focused echo in life support
- (c) Maximum student:instructor ratio – 5:1
- (d) Live ultrasound models for scanning sessions, preferably including both normal subjects and patients with demonstrable pathology (e.g. peritoneal dialysis patients, patients with known abdominal aortic aneurysm). Patients or professional-grade simulators are preferable for abnormal anatomy. However, they may not always be readily available. In such cases, ultrasound cineloops showing the same pathology may be substituted. Education programs covering Focused Echo in Life Support (FELS) must fulfil the criteria outlined in the ACEM policy document.

5. Education program content

5.1 Physics

- Piezoelectric effect
- Wave characteristics – cycle, frequency, period, wavelength, amplitude
- Echogenicity
- Image resolution
- Attenuation
- Doppler effect
- Impedance
- Artefacts
- Bio-effects

5.2 Instrumentation

- Transducer types and selection
- Transducer manipulation
- Image labelling
- Focus
- Gain
- Time gain compensation
- Orientation
- Scan planes
- Image measurement
- Infection control
- Machine care and maintenance

For each area of focused ultrasound (5.3 onwards), the following should be covered:

- introduction
- superficial and sonographic anatomy
- sonographic protocols
- clinical algorithms and integration
- limitations / pitfalls
- reporting

5.3 Extended Focused Assessment with Sonography in Trauma (EFAST)

5.3.1 Anatomy

- Liver
- Spleen
- Kidneys
- Pericardium
- Lung bases
- Bladder
- Uterus
- Ribs pleural line

5.3.2 EFAST Practical

- Right upper quadrant/Morison's pouch
- Left upper quadrant/spleno-renal area
- Subxiphoid
- Pelvic
- Diaphragm
- Lung

5.3.3 EFAST findings

- Haemoperitoneum
- Haemopericardium
- Haemothorax
- Pneumothorax
- Limitations / pitfalls
- Reporting

5.3.4 Integration into clinical practice and algorithms

- Blunt versus penetrating injury

5.4 Abdominal aortic examination

Anatomy

- Aorta and major branches
- Inferior vena cava
- Vertebral bodies

Abdominal aorta practice

- Aorta longitudinal and transverse with measurements
- Appearance of thrombus
- Inferior vena cava

Findings

- Abdominal aortic aneurysm
- Ectatic aorta
- Limitations / pitfalls
- Reporting

Integration into clinical practice algorithms

- Haemodynamically unstable patient
- Pulsatile mass
- Back pain
- Flank pain

5.5 Focused Echocardiography in Life Support

Anatomy

- Cardiac chambers
- Cardiac valves
- Pericardium
- Great vessels
- Lung

Echocardiography Practice

- Parasternal long axis
- Parasternal short axis
- Apical 4 and 5 chamber
- Subcostal long and short axis
- Inferior vena cava

Findings

- Pericardial effusion and tamponade

- Left ventricular size and systolic function
- Right ventricular size and systolic function
- Estimation of volume status
- Limitations / pitfalls
- Reporting

Integration into clinical practice algorithms

- Haemodynamically unstable patient
- Cardiac arrest
- Education programs should provide participants with a simple report form for use in the peri-arrest / arrest setting, which states the limited nature of the examination performed and what clinical questions have and have not been answered. This is vital to avoid confusion with the information that would be obtained by a comprehensive echocardiogram.

5.6 Introduction to procedural ultrasound

- Relevant anatomy
- Indications/contraindications and complications
- Limitations/pitfalls
- Reporting
- Practical sessions using phantoms

General principles

- Direct vs indirect method
- In-plane vs out-of-plane model
- Principles of infection control
- Reporting

Vascular access

- Venous and adjacent anatomy
- Arterial and adjacent anatomy
- Limitations/pitfalls
- Reporting
- Practical sessions using phantoms

Pleural and abdominal aspirations

- Anatomy
- Fluid identification
- Loculation identification
- Limitations/pitfalls
- Reporting

- Practical sessions

Foreign Body

- Identification
- Methods of removal
- Limitations/pitfalls
- Reporting
- Practical sessions using phantoms

Nerve and fascial plane blocks

- Regional anatomy
- Local anaesthetic toxicity
- Limitations/pitfalls
- Reporting

5.7 Lung ultrasound

Anatomy

- Lung surface markings of upper, middle and lower lobes
- Lung 'zones' – describe zones 1 to 4 (international consensus) and Lichtenstein's zones
- Diaphragm
- Ribs
- Pleural surface
- Spine
- Heart
- Liver
- Spleen

Practical

- Optimise machine preset/settings to scan lungs
- Scan lung zones 1 to 4
- Identify diaphragms and lung curtain
- Identify ribs, intercostal space, pleural line
- Identify lung sliding
- Identify lung pulse
- Identify comet tail and other artefacts

Pathology (likely to require simulated cases, as patients are not always available/suitable)

- Normal lung
- Absent lung sliding (and how to differentiate causes)

- Focal B lines
- Diffuse B lines
- Consolidation
- Pleural effusion

Integration – clinical cases

- Pneumonia
- Interstitial syndrome
- Cardiogenic pulmonary oedema
- Lung fibrosis
- Pneumothorax
- Pleural effusion
- Integration of lung ultrasound into resuscitation (initial assessment and in monitoring response e.g. early evidence of fluid overload)

Pitfall cases.

Note: Additional modalities may be included at the discretion of local providers.

6. ACEM recognition

Previously ultrasound workshops required ACEM approval to become a ‘recognised’ course for training purposes. However, due to the large number of courses and the limitations of the review process itself, ACEM recognition of these workshops is no longer required. Participants should check the program to decide whether it meets their needs. CPD approval will continue to be required as per standard processes. It is hoped that the removal of the review process will encourage providers to be as creative as possible to ensure that optimal learning and retention of skills and knowledge occurs.