

# Clinical Significance of US Artifacts<sup>1</sup>

Michael Baad, MD  
Zheng Feng Lu, PhD  
Ingrid Reiser, PhD  
David Paushter, MD

**Abbreviations:** SPL = spatial pulse length, SRI = speckle reduction imaging, TGC = time-gain compensation, THI = tissue harmonic imaging

**RadioGraphics** 2017; 37:1408–1423

<https://doi.org/10.1148/rg.2017160175>

**Content Codes:** **PH** **SQ** **US**

<sup>1</sup>From the Department of Radiology, University of Chicago, 5841 S Maryland Ave, MC 2026, Chicago, IL 60637. Presented as an education exhibit at the 2015 RSNA Annual Meeting. Received July 8, 2016; revision requested September 21 and received October 18; accepted October 27. For this journal-based SA-CME activity, the authors, editor, and reviewers have disclosed no relevant relationships. **Address correspondence** to Z.F.L. (e-mail: [zlu@radiology.bsd.uchicago.edu](mailto:zlu@radiology.bsd.uchicago.edu)).

©RSNA, 2017

## SA-CME LEARNING OBJECTIVES

*After completing this journal-based SA-CME activity, participants will be able to:*

- Describe the appearances and underlying physical mechanisms of common gray-scale US artifacts.
- Identify strategies to mitigate or accentuate US artifacts, depending on the clinical application.
- Discuss the effects of newer US modes on artifact appearance.

See [www.rsna.org/education/search/RG](http://www.rsna.org/education/search/RG).

Artifacts are frequently encountered at clinical US, and while some are unwanted, others may reveal valuable information related to the structure and composition of the underlying tissue. They are essential in making ultrasonography (US) a clinically useful imaging modality but also can lead to errors in image interpretation and can obscure diagnoses. Many of these artifacts can be understood as deviations from the assumptions made in generating the image. Therefore, understanding the physical basis of US image formation is critical to understanding US artifacts and thus proper image interpretation. This review is limited to gray-scale artifacts and is organized into discussions of beam- and resolution-related, location-related (ie, path and speed), and attenuation-related artifacts. Specifically, artifacts discussed include those related to physical mechanisms of spatial resolution, speckle, secondary lobes, reflection and reverberation, refraction, speed of sound, and attenuation. The underlying physical mechanisms and appearances are discussed, followed by real-world strategies to mitigate or accentuate these artifacts, depending on the clinical application. Relatively new US modes, such as spatial compounding, tissue harmonic imaging, and speckle reduction imaging, are now often standard in many imaging protocols; the effects of these modes on US artifacts are discussed. The ability of a radiologist to understand the fundamental physics of ultrasound, recognize common US artifacts, and provide recommendations for altering the imaging technique is essential for proper image interpretation, troubleshooting, and utilization of the full potential of this modality.

©RSNA, 2017 • [radiographics.rsna.org](http://radiographics.rsna.org)

## Introduction

Ultrasonography (US) uses the interaction of acoustic energy within a target medium to produce an image that reveals information about the target's structure and composition. A short ultrasound pulse emitted by a transducer is transmitted into the body along a narrow well-defined ultrasound beam. Echo signals are generated within the ultrasound beam as the pulse travels through the tissues, undergoing reflections and scatterings by tissue structures. The echo signals returning to the transducer are used for image formation. Three basic assumptions are made for standard pulse-echo US image formation. First, it is assumed that the ultrasound pulse travels in a straight line, giving rise to echo signals within the same narrow beam. This received echo is assumed to have been derived from the most recently transmitted pulse. Second, it is assumed that the speed of sound in tissues is constant at 1540 m/sec and that the time delay between the transmitted pulse and the received echo is directly related to the depth at which the echo is generated. Third, it is assumed that the echo strength, modulated into various brightness levels on a B-mode image, only encodes tissue

## TEACHING POINTS

- Lateral resolution is limited by the beam width, which varies with depth and is narrowest at the focal zone. Therefore, lateral resolution is optimal at the focal zone and deteriorates in the near and far fields.
- Speckle (granular texture) on a US image is caused by constructive and destructive interference of ultrasound waves interacting with microstructures in tissue. The speckle characteristics are dependent on properties of the imaging system (eg, ultrasound frequency, beam shape) and the tissue's properties (eg, scatterer size distribution, acoustic impedance differences). Speckle reduces image contrast and lesion detectability. Speckle can be decreased with proprietary postprocessing algorithms (speckle reduction imaging) on most modern US units. Spatial compounding and THI also reduce speckle.
- In creating the US image, the depth of an echo is calculated from the time delay between transmitting a pulse and receiving an echo, with an assumption of a constant sound speed of 1540 m/sec in soft tissue. If the speed of sound in the tissue is actually less, such as in fat (1450 m/sec), it will take relatively longer for the echo to be received, and it will be displayed as if it originated from a more distant target. Conversely, if the speed of sound is greater, the echo will appear closer.
- As an ultrasound wave travels through tissue, its amplitude reduces with increasing distance, which is termed *attenuation*. Although absorption is usually the dominant mechanism to cause attenuation, acoustic reflection, scattering, and divergence of the beam also contribute to attenuation.
- To use certain image artifacts for diagnosis, such as shadowing behind a stone, one should understand conditions producing the artifacts. Inappropriate focal zone placement, excessive beam widths, and spatial compounding will decrease shadowing. As some degree of spatial compounding is built into many imaging protocols on modern US units, it is important to turn this off when imaging stones. Conversely, imaging with increased frequency probes and use of THI will increase shadowing.

echogenicity (1). This implies that attenuation is adequately compensated by first-order correction schemes such as time-gain compensation (TGC).

This is the idealized model by which an US image is created. However, all of these assumptions are violated to various degrees, resulting in a range of different imaging artifacts. In a certain respect, clinical US itself can be interpreted as a collection of imaging artifacts. Some artifacts result in image degradation and are generally unwanted, whereas others reveal valuable information about the underlying tissue being imaged. Understanding the underlying physics of ultrasound and the assumptions used for US image formation is important for understanding US artifacts.

In this review, the underlying physical principles are emphasized, which aids in understanding these artifacts and vice versa. Artifacts discussed are those related to beam and resolution (Table 1), location (Table 2), and attenuation (Table 3) characteristics. Doppler US-based artifacts are not discussed. Understanding the physical basis of US

artifacts is a critical component of US image interpretation, both in avoiding pitfalls from unwanted artifacts and in improving interpretation.

## Beam- and Resolution-related Artifacts

### Beam-width Artifact

Beam-width artifact is a manifestation of lateral resolution, which refers to the ability to discriminate two closely spaced points at the same depth within the imaging plane as distinct. Lateral resolution is limited by the beam width, which varies with depth and is narrowest at the focal zone (Fig 1). Therefore, lateral resolution is optimal at the focal zone and deteriorates in the near and far fields. Beam-width artifact refers to the lateral blurring of a point target that occurs as echoes from the same target are insonated at adjacent beam positions. Similarly, if two adjacent point targets are separated by a distance less than the beam width, they will appear as one. The beam width decreases as the wavelength decreases; thus the beam width is narrower with higher-frequency transducers. Focusing is a process used to further improve the beam width so that it is narrowest at the focal zone. When electronic focusing is used, a defocusing effect can occur from imaging tissues that have a different speed of sound from what is assumed (usually 1540 m/sec), in a process called phase aberration. This results in a wider beam width and a degradation of lateral resolution (Fig 2). This loss in lateral resolution can be offset by changing the underlying assumed speed of sound (discussed later). Lateral resolution, and thus beam-width artifact, can be improved through dynamic receive focusing and by using multiple transmit focal zones.

### Section-thickness Artifact

Section-thickness artifact is related to elevational resolution, which refers to the ability to discriminate two points as distinct in a direction perpendicular to the imaging plane. Elevational resolution is usually the most limited component of spatial resolution and is less in the near and far fields, similar to lateral resolution. Section-thickness artifact is caused by echo-signal averaging within the section thickness (Fig 3). It is often clinically noticeable as low-level echoes in an anechoic structure. It is important to recognize these echoes as artifacts, as they may mimic debris in the bladder or sludge in the gallbladder. In conventional array transducers, a single row of crystal elements is used, resulting in no control over the elevational resolution with depth. Limited elevational focal length and elevational resolution is the underlying rationale for use of an acoustic standoff of gel or a standoff pad

**Table 1: US Artifacts due to Beam and Resolution Characteristics**

Type of Artifact	Physics Mechanism	Alteration of Artifacts	Clinical Relevance
Beam width	Poor lateral resolution	Can be reduced by dynamic receive focusing, multiple-transmit FZs, increasing frequency, FZ placement, local speed of sound selection	Lateral blurring of point targets, aberrant echoes from adjacent highly echogenic objects
Section thickness	Poor elevational resolution	Can be reduced by positioning the area of interest in FZ with a standoff pad or by using 1.5D/2D transducer arrays	Mimics debris in anechoic structures, aberrant internal echoes in small cysts and vessels
Axial resolution	Axial resolution	Better with increasing frequency	Choose a higher frequency for better axial resolution
Speckle noise	Acoustic interference causing granular appearance	Can be reduced by SRI, SCI, THI	Degrades spatial and contrast resolution but also gives tissues their characteristic image texture
Secondary lobe Side lobes Grating lobes	Echoes transmitted outside primary beam are reflected back to transducer	Can be reduced by THI, decreasing gain, changing AOI, using multiple windows, advanced transducer design	Mimics debris in anechoic structures

Note.—AOI = angle of insonation, FZ = focal zone, 1.5D = 1.5-dimensional, SCI = spatial compound imaging, SRI = speckle reduction imaging, THI = tissue harmonic imaging, 2D = two-dimensional.

when imaging superficial structures (such as cysts), which is common at breast US. The extra distance provided by the standoff allows the superficial structure to be imaged at the elevational focal zone, reducing section-thickness artifact. By reducing these low-level echoes, cystic lesions can be more confidently differentiated from solid lesions. Alternatively, 1.5D transducer arrays with multiple rows of crystal elements or 2D arrays can improve elevational resolution by using electronic focusing and variable apertures in the elevational direction (2).

### Axial Resolution

Axial resolution refers to the ability to discriminate two adjacent points along the axial direction and is usually superior to elevational and lateral resolution. A pair of interfaces can be separated if the distance between them is greater than one-half the spatial pulse length (SPL), to avoid overlap of returning echoes (Fig 4). Objects spaced less than one-half of the SPL will not be resolved as separate. The SPL is determined by the number of cycles in the emitted pulse multiplied by the ultrasound wavelength. Since higher frequencies will have a shorter wavelength and thus a shorter SPL, the axial resolution is better with higher frequencies. As opposed to elevational and lateral resolution, axial resolution is independent of depth.

### Speckle Noise

Speckle (acoustic interference) refers to the inherent granular appearance within tissues

that results from interactions of the beam with small-scale interfaces that are about the size of a wavelength or smaller. Whereas specular reflectors follow the laws of reflection, these nonspecular reflectors scatter the beam in all directions. Scatterings from these individual small interfaces combine through an interference pattern to form the visualized granular appearance. Speckle appears as noise within the tissue, degrading spatial and contrast resolution but also giving tissues their characteristic image texture. Because nonspecular reflectors reflect sound in all directions, they result in much-lower-amplitude echoes returning to the transducer and are not affected by the angle of insonation. Speckle (granular texture) on a US image is caused by constructive and destructive interference of ultrasound waves interacting with microstructures in tissue (3). The speckle characteristics are dependent on the properties of the imaging system (eg, ultrasound frequency, beam shape) and the tissue's properties (eg, scatterer size distribution, acoustic impedance differences). Speckle reduces image contrast and lesion detectability. Speckle can be decreased with proprietary postprocessing algorithms (speckle reduction imaging) on most modern US units (Fig 5). Spatial compounding and THI also reduce speckle.

### Secondary Lobe Artifacts

Secondary lobe artifacts arise from reflections of unwanted ultrasound energy directed off-axis

**Table 2: US Artifacts due to Location (Path or Speed) Characteristics**

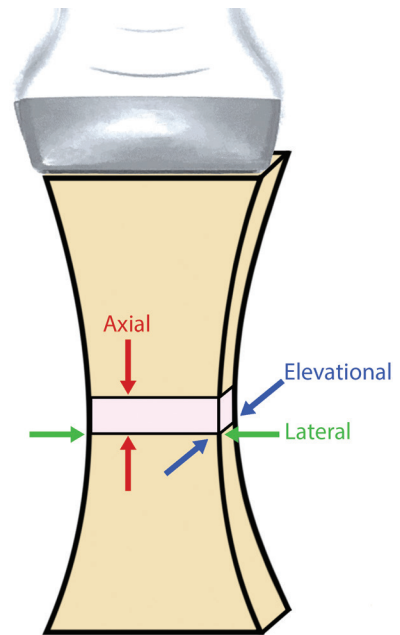
Type of Artifact	Physics Mechanism	Alteration of Artifacts	Clinical Relevance
Reverberation	Reflections between highly reflective interfaces in parallel	Can be reduced by using THI, decreasing gain, changing AOI, and using multiple windows	Usually unwanted, mimicking debris within cystic structures; may be useful, as in abnormal air
Comet tail	Reverberations from closely spaced highly reflective interfaces	May be more visible by using THI and less visible by using SCI	Adenomyomatosis, colloid nodules, calcifications, foreign bodies, surgical clips, IUDs
Ring down	Resonant vibrations within air bubbles	May be reduced by using SCI	Abnormal air (abscesses, pneumoperitoneum, PVG, emphysematous infections, pneumobilia), normal air (bowel loops, appendix), B-lines
Mirror image	Reflections off a strong specular reflector produce a mirror image of an object	May be reduced by decreasing gain, changing AOI, using multiple imaging windows	Mimics disease, such as pseudothickened bowel wall and consolidated lung
Multipath	Small off-axis reflections on path to or from primary reflector	May be altered by varying AOI or imaging window	General image degradation
Refraction Misregistration Ghosting Edge shadowing	Refraction at oblique interfaces causes altered location of objects, duplication of underlying structures, and/or shadowing at edges	May be reduced by varying AOI or imaging window	False position of lesions during biopsy, can mimic duplication of structures (gestational sac, spinal cord, aorta), cyst characterization by using edge shadowing
Speed of sound Boundary distortion Misregistration of targets Errors in size Phase aberration	A constant speed of sound is used to calculate depth in soft tissues, but there actually is variability among different tissues	Modern US units allow manual speed of sound correction	Inaccurate locations and measurements of structures in axial dimension, loss of lateral resolution, bayonet artifact
Range ambiguity	Echoes deep to imaging range are depicted within range on the next pulse	May be reduced by reducing PRF, reducing the number of FZs, increasing the image depth	Mimics debris in large fluid-filled structures

Note.—AOI = angle of insonation, FZ = focal zone, IUD = intrauterine device, PRF = pulse repetition frequency, PVG = portal venous gas, SCI = spatial compound imaging.

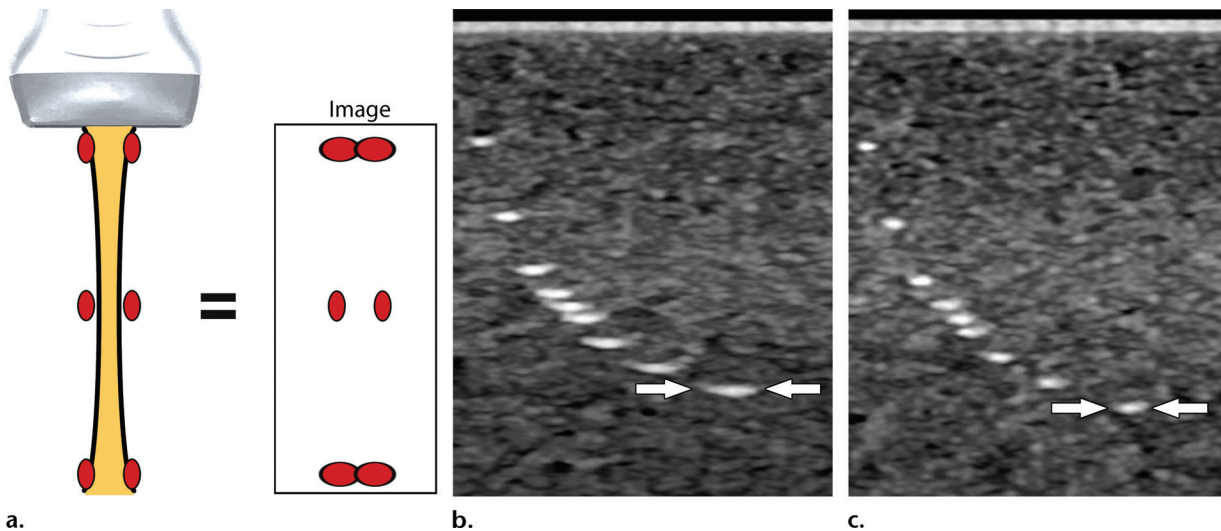
**Table 3: US Artifacts due to Attenuation Characteristics**

Type of Artifact	Physics Mechanism	Alteration of Artifacts	Clinical Relevance
Increased through transmission	Increased intensity of echoes distal to a low-attenuating structure	May be increased by using THI	Differentiation of cystic from solid structures
Acoustic shadowing Clean Partial Dirty	Reduction in echo strength distal to a highly attenuating or reflective object	Increases with increased frequency and THI; decreases with inappropriate FZ placement, excessive beam width, and SCI	Detection of stones, calcification, and air

Note.—FZ = focal zone, SCI = spatial compound imaging.



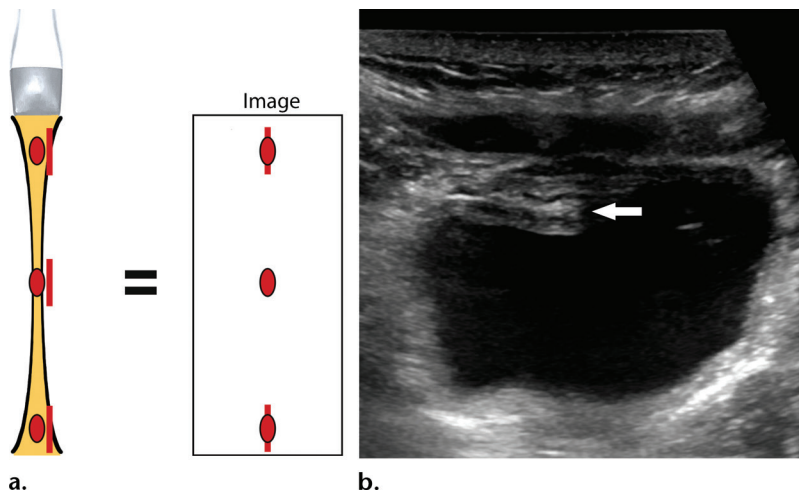
**Figure 1.** Diagram shows the ultrasound beam profile and components of spatial resolution, including axial, lateral, and elevational resolution. At the focal distance, the beam width and section thickness narrow; thus the lateral and elevational resolutions are at their highest. In contrast, although axial resolution is frequency dependent, it is independent of depth.



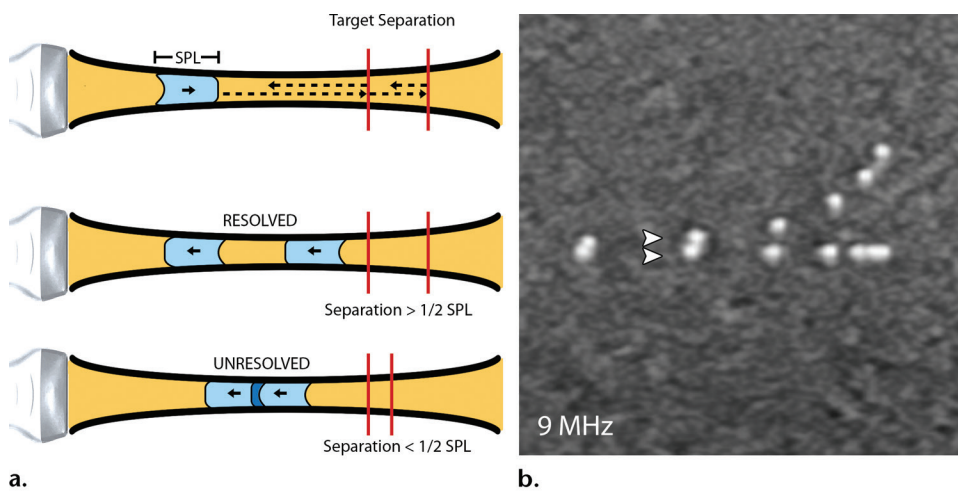
**Figure 2.** Beam-width artifact (lateral resolution). (a) Diagram shows the effect of depth on lateral resolution. In the near and far fields, the beam width is wide and will register a target at multiple overlapping beam positions, resulting in lateral streaking. Thus, two point targets separated by the same distance will appear as one, whereas they may be resolved at the focal distance. (b, c) US images obtained at two different speeds of sound in a rubber phantom with an intrinsic speed of sound of 1450 m/sec demonstrate the concept of lateral resolution. (b) Poor lateral resolution with lateral blurring (arrows) of the point echoes is observed when the speed of sound value used by the US unit (1540 m/sec) differs from that of the phantom material (1450 m/sec). (c) Improved lateral resolution with less blurring (arrows) is achieved when the speed of sound value used by the US unit is adjusted to match the speed of sound of the phantom material.

from the main beam and include side lobes and grating lobes. Most of the sound energy is transmitted within the center of the primary beam. However, a small amount (approximately 1%) is emitted at several angles outside the primary beam as side lobes, due to the radial expansion and contraction of the individual transducer elements (Fig 6) (4). When these weak side lobes encounter a highly reflective surface, they can be reflected back to the transducer. Since US assumes that all returning echoes arise from the primary

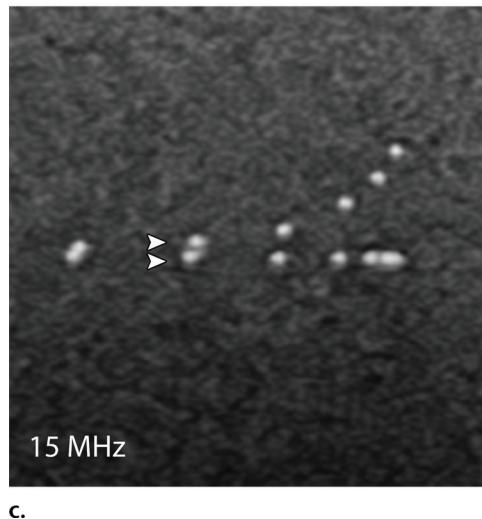beam, the echoes are falsely displayed within beam instead of at their true location. Because they are so low energy, they are often not recognizable as discrete structures when they occur in soft tissues. However, in anechoic structures, side lobes are sometimes seen as hyperechoic objects or diffuse echoes. A common example of a side lobe artifact is the appearance of pseudosludge within the gallbladder from adjacent gas in bowel loops reflecting side lobes. Pseudosludge typically has a convex curved margin and may disappear



**Figure 3.** Section-thickness artifact (elevational resolution). (a) Diagram of the side of the transducer shows volume averaging occurring in the elevational plan, with section-thickness artifact minimized at the focal zone. An object (red bars, at differing apparent depths) adjacent to the target (ellipses, at differing apparent depths) will be superimposed on the target in the near and far fields. (b) Transverse US image of the normal bladder in a 14-year-old girl shows artifactual echoes (arrow) that appear to be within the bladder from an adjacent bowel loop. A side-lobe artifact may have also contributed to these echoes.



**Figure 4.** Axial resolution. (a) Diagram shows the relationship of axial resolution to the SPL, which is inversely related to frequency. Arrows = beam path over time. Top: A single beam approaches two targets (red bars). Middle: If these targets are separated by a distance greater than one-half the SPL, they will be resolved. Bottom: If the separation is less than one-half the SPL, the returning echoes will overlap and they will not be resolved. (b, c) US images of echogenic foci (arrowheads) in phantoms demonstrate an improvement in axial resolution when the frequency increased from 9 MHz (b) to 15 MHz (c).

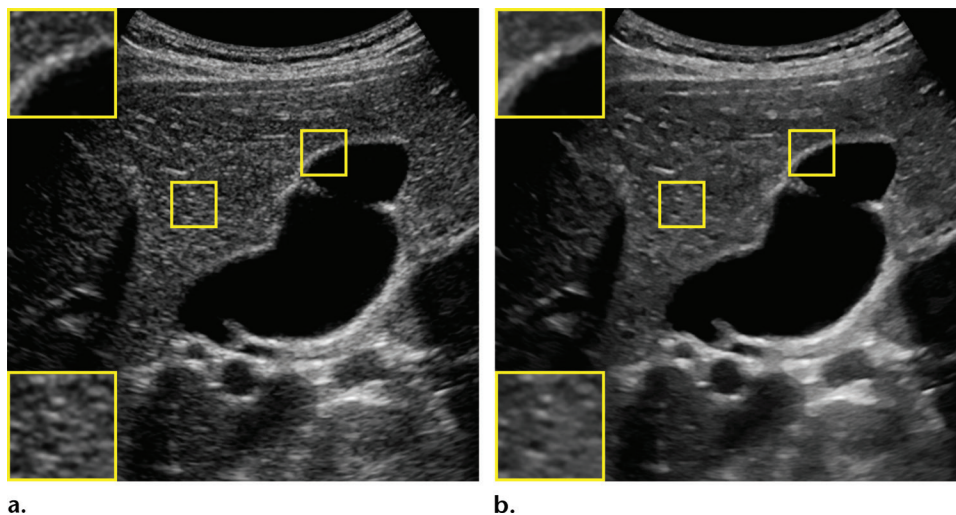


with repositioning, whereas true sludge has a flat margin and layers with changes in patient position. In addition, reducing the gain will reduce low-energy secondary lobes and pseudosludge, whereas true sludge will remain. Efforts have been made in the design of transducers, by using methods such as apodization (reducing the rela-

tive pulse amplitude and receive amplification of the outer transducer elements) to reduce side lobe artifacts, yet some contribution will always be present (5). Side lobe artifacts can be reduced by repositioning the patient, changing the transducer angle, or reducing the gain (4). In practice, imaging from multiple angles is helpful in discriminating artifact from a true finding.

Grating lobe artifact occurs in a similar manner to side lobe artifacts, in which far off-axis grating lobes result in an error in positioning the returning echoes. Compared with side lobes, grating lobes occur at more oblique angles (up to 90°) relative

**Figure 5.** Speckle (acoustic interference) at US of the normal bladder in a 12-year-old girl. Transverse US images were obtained without (a) and with (b) SRI. Speckle results from a complex interference pattern that gives a granular appearance, which is best demonstrated in the liver parenchyma (bottom left insets). SRI is a postprocessing technique performed after image acquisition that reduces speckle and results in edge enhancement (top left insets).



to the primary beam and have a different origin. They are produced as a result of a discontinuous transducer surface comprised of multiple individual elements regularly spaced across the aperture that cause constructive interference of the ultrasound beam between adjacent elements of the array (6). When grating lobe artifacts occur, they are at higher amplitudes than side lobe artifacts and are closer in intensity to that of the primary beam (5). These artifacts are dependent on the spacing between individual transducer elements and will not occur if the interelement spacing is less than one-half the wavelength (2). Therefore, their effect will depend on the particular transducer being used and the transducer frequency. THI results in suppression of grating lobes.

### Location (Path or Speed)–related Artifacts

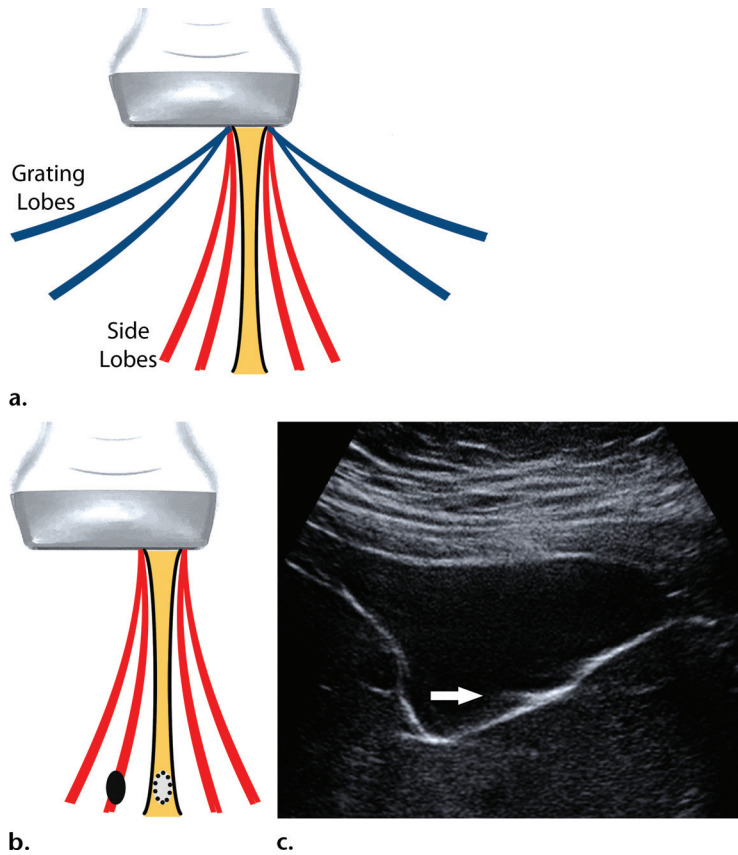
The US reconstruction algorithm assumes that an echo returns to the transducer after a single reflection and that the time in which the echo returns is used to calculate the depth of the signal. Violations to this assumption are the basis of a number of commonly encountered artifacts. When a beam encounters a smooth large boundary (specular reflector), the reflection coefficient of the beam amplitude is proportional to the differences in acoustic impedance between the two tissues. For example, at a muscle-fat interface, approximately 1% of the beam is reflected, whereas at a muscle-air interface, nearly 100% is reflected (7).

### Reverberation Artifacts

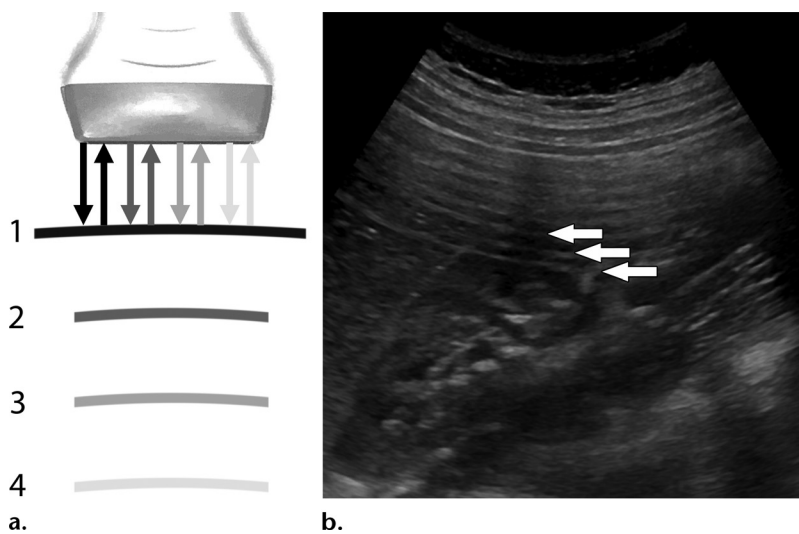
Reverberation artifacts arise when the beam encounters two highly reflective interfaces in

parallel. Instead of the beam reflecting off a single surface and producing a strong echo that returns to the transducer, the ultrasound beam is reflected between the interfaces back and forth multiple times (Fig 7). These reflected echoes are interpreted as occurring at increasing depths since they take longer to be received by the transducer. This appears as multiple bright parallel lines at uniform intervals that decrease in intensity with increasing depths. They are often caused by reflections between a highly reflective surface in the near field and the transducer itself but may arise at any highly reflective interface, including those involving air, metal, and calcium. This artifact is one of the most common sources of degradation in image quality but can occasionally be useful in identifying air in abnormal locations, such as may be seen with pneumatosis, pneumoperitoneum, and pneumobilia (8,9). Reverberation artifact may be minimized by selecting a different imaging plane to avoid the reflective surfaces or by changing the angle of insonation. THI will also decrease reverberation artifact, particularly in the near field where few harmonics are generated (10).

Comet-tail artifact is a special subtype of reverberation artifact caused by highly reflective interfaces that are so closely spaced that the individual echoes are not discernible. In addition, attenuation of more delayed echoes results in a progressively decreased amplitude and width with increasing depths (Fig 8). Therefore, this artifact is based on the same principles of reverberation but resembles a comet tail, appearing as a tapering echogenic triangle or cone distal to a strongly reflecting structure. Compared with conventional



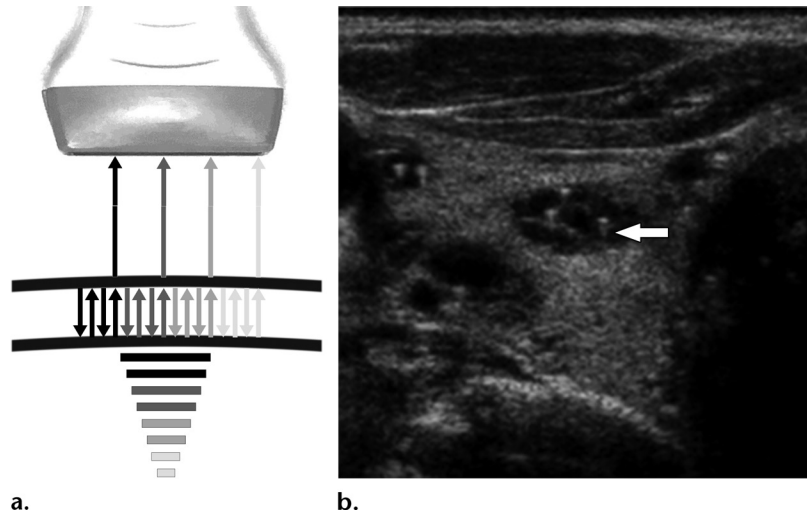
**Figure 6.** Secondary lobe artifacts. (a) Diagram shows multiple secondary lobes occurring around the primary beam. Side lobes (red) are low-energy (up to 1% of the primary beam energy) off-axis beams immediately adjacent to the primary beam occurring in all transducers, whereas grating lobes (blue) occur at more oblique angles, may be stronger, and are transducer dependent. (b) A highly reflective object (black ellipse) immediately adjacent to the current beam position can reflect secondary lobes, falsely displaying those echoes at that beam position (dotted ellipse). (c) Longitudinal US image of the normal gallbladder in a 55-year-old woman shows a side lobe artifact (arrow) in the gallbladder lumen, a finding that arises from the adjacent echogenic wall.



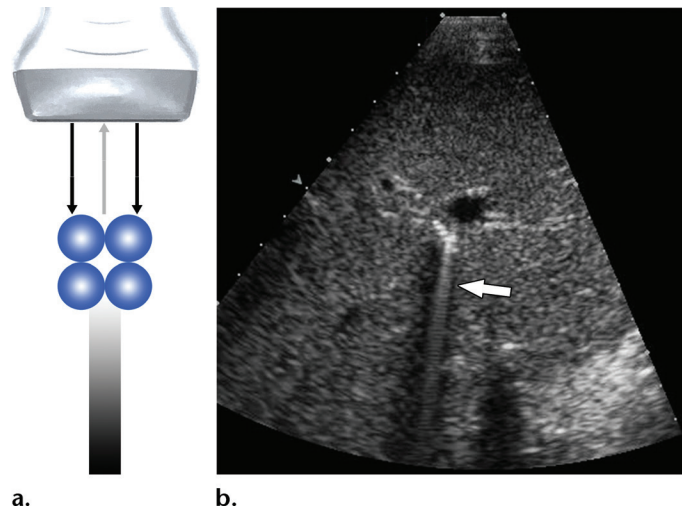
**Figure 7.** Reverberation artifact. (a) Diagram shows the ultrasound beam reflecting repeatedly between two strongly reflective interfaces in parallel, one of which is the transducer face. Some of the energy of the first returned echo is reflected at the transducer face and acts like a second weakly transmitted pulse, which is again reflected back toward the transducer at the interface. This can occur multiple times and appears as weakening echoes (increasingly light arrows) at integer multiples of the depth of the reflecting interface. (b) Longitudinal US image of a normal kidney in a 9-year-old girl shows multiple body wall reverberation artifacts (arrows) in the near field that obscure the image.



**Figure 8.** Comet-tail artifact. (a) Diagram shows multiple reverberations occurring between two closely spaced reflective interfaces, producing a comet-tail artifact. The interfaces themselves are not discernible. However, as the number of reflections increases, the perceived depth increases and the amplitude decreases (increasingly light arrows), resulting in a tail appearance. (b) Transverse US image of the thyroid in a 57-year-old woman shows multiple comet-tail artifacts (arrow) in the cystic thyroid nodule, findings diagnostic for a benign colloid cyst.



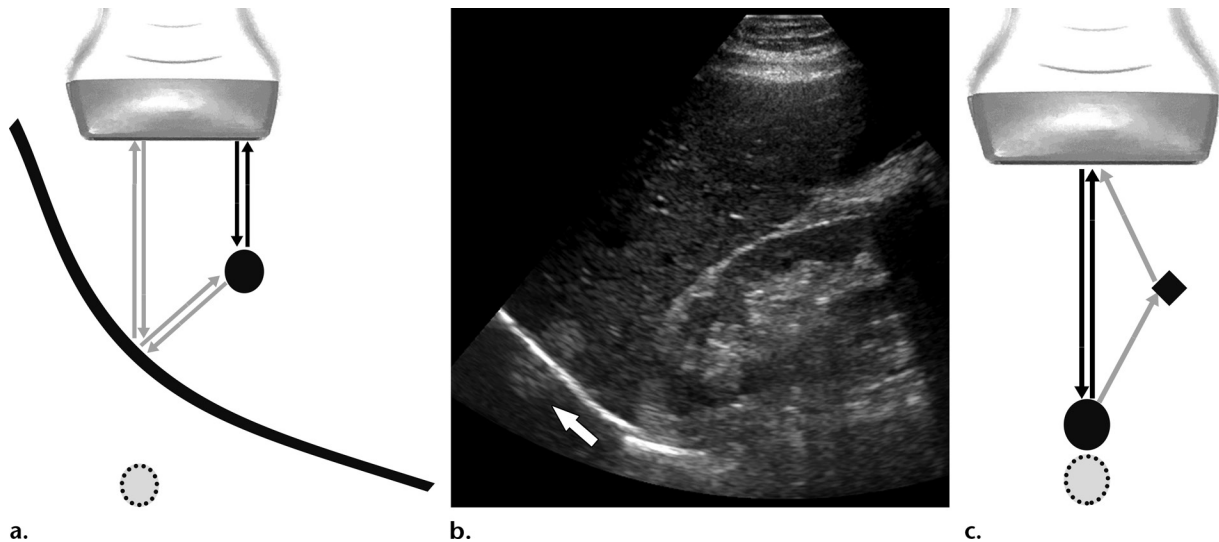
**Figure 9.** Ring-down artifact. (a) Diagram shows interactions of the primary beam with tetrahedral arrangements of air bubbles, resulting in a continuous wave of sound transmitted back to the transducer from resonant vibrations. (b) Longitudinal US image of the liver in a 61-year-old man shows ring-down artifact (arrow) from pneumobilia. The highly reflective interface also results in distal shadowing.



reverberation artifacts, comet-tail artifacts arise from closely spaced interfaces that are not resolvable and decrease in width with depth. Comet-tail artifacts are clinically useful, particularly in identifying cholesterol crystals in adenomyomatosis of the gallbladder or inspissated colloid in benign colloid nodules of the thyroid. They may also be seen with small calcifications and metal objects, such as foreign bodies and surgical clips.

Ring-down artifacts appear similar to reverberation artifacts, and although they may resemble comet tail artifacts, the mechanism is distinctly different (11). Instead of closely spaced reflective interfaces, ring-down artifacts arise from resonant vibrations within trapped tetrahedrons of air bubbles (Fig 9) (7). These resonant vibrations produce a continuous, though decaying, sound wave transmitted back to the receiver, appearing as a streak or series of parallel bands deep to a focus of gas. Whereas artifact from normal air-filled structures may obscure evaluation of deeper structures, ring-down artifact can be useful in

identifying abnormal foci of air. The presence of ring-down artifact may indicate significant underlying disease, such as pneumoperitoneum or portal venous gas. Similarly, echogenic foci and ring-down artifact may also be seen with emphysematous (gas-forming) infections and abscesses. Alternatively, the presence of air can be a reassuring sign if identified in the appendix in cases of suspected appendicitis. Ring-down artifact contributes to the phenomenon of dirty shadowing, which is discussed later. More recently, ring-down artifacts (B-lines) have been used at lung US in the diagnosis of interstitial pathologic conditions (12). Again it must be emphasized that by definition, ring-down artifact is from air and not from metal, calcium, or cholesterol crystals found with comet-tail artifact. However, metal sometimes produces artifact that resembles ring-down artifact. Current US units may minimize ring-down and comet-tail artifacts and therefore decrease the potential to recognize abnormal gas collections. Spatial compounding



**Figure 10.** Mirror image and multipath artifacts. **(a)** Diagram shows mirror image artifact produced from a strong specular reflector. The transmitted ultrasound beam (gray arrows) reflects off the specular reflector (curved black line), encounters a target (black circle), and is then reflected back along its transmitted course. Because of the increased time to echo return, the image (dotted circle) appears to be deep to the reflector at that inappropriate beam path. At a different beam path (black arrows), the target is appropriately imaged in the correct location. The result is a mirror image appearance across the specular reflector. **(b)** Longitudinal US image of the liver in a 44-year-old man shows a mirror image artifact (arrow) of a hepatic hemangioma, which appears across the diaphragm within the lung. **(c)** Diagram shows multipath artifact, whereby the primary beam (black arrows) encounters a target (black circle), is reflected back (gray arrows) but slightly off axis, and encounters a second, adjacent reflector (diamond) before returning to the transducer. The result is a slightly increased time to echo return, with the target appearing artifactually deep (dotted circle).

should be turned off when intentionally imaging either comet-tail or ring-down artifacts because it produces wider and more divergent artifacts with decreased intensity (13). THI, however, may improve visualization, with sharper comet tails (10).

### Mirror Image and Multipath Artifacts

Mirror image artifacts result from the false assumption that an echo returns to the transducer after a single reflection. As opposed to reverberation artifacts, which occur between two strong reflectors in parallel, mirror image artifacts are produced when the beam encounters a target after being reflected off a single strong specular reflector (Fig 10a, 10b). A portion of the beam is reflected from the target back along its transmitted course, again off the specular reflector and back to the transducer. The second image of the target is therefore generated along that path, deeper than the true location owing to the increased time to echo return. The prototypical example is a liver lesion adjacent to the diaphragm, whereby the transmitted beam is reflected off the diaphragm and encounters a liver lesion that subsequently reflects it back toward the diaphragm and then to the transducer. The resultant image contains two lesions equidistant from but on opposite sides of the diaphragm. In addition to the diaphragm, these artifacts may occur adjacent to any strong reflector such as the pleura, bladder, and bowel. Avoiding these artifacts is important because a mirror image artifact may simulate an

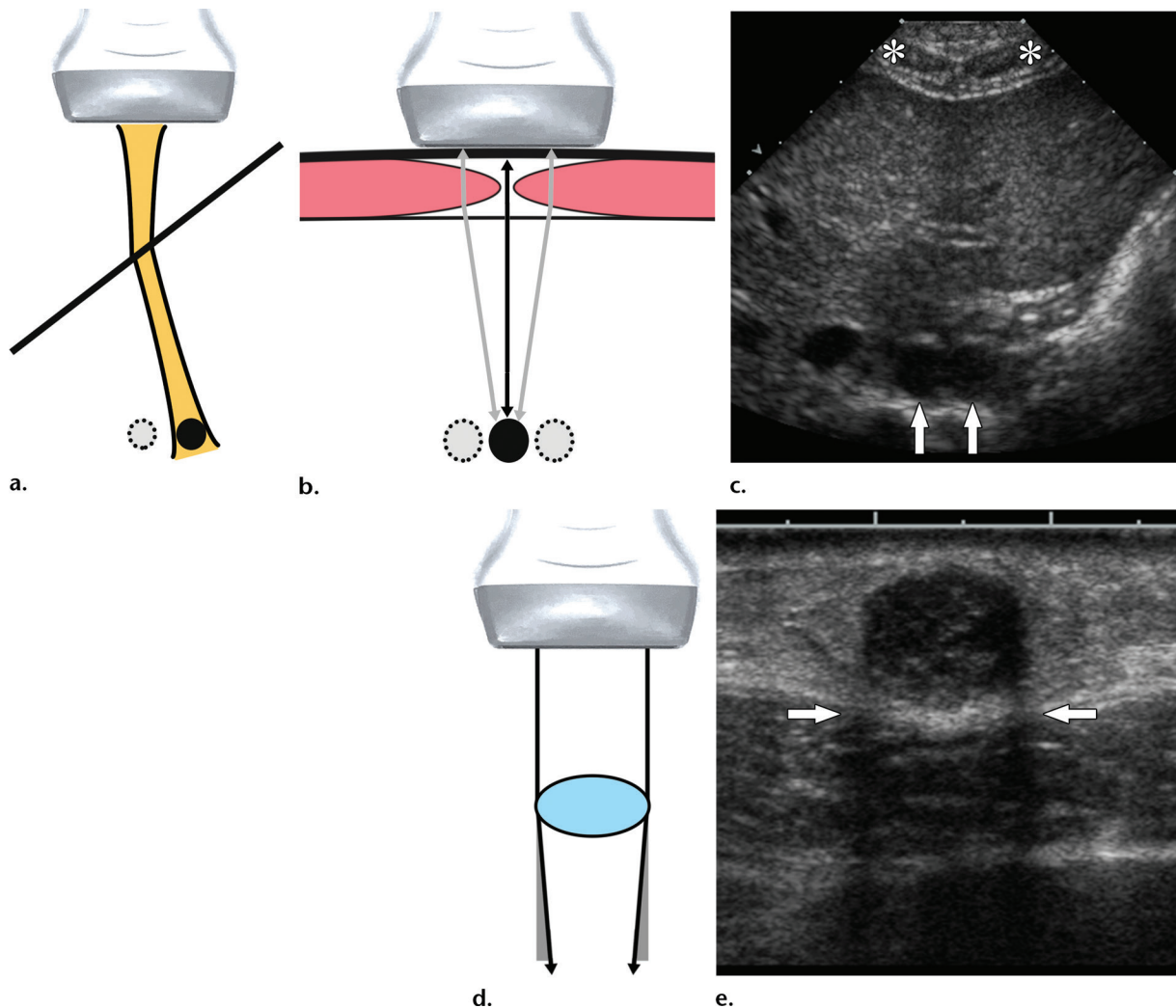
abnormal pathologic condition such as pseudothickened bowel wall or consolidated lung. Mirror image artifacts, which also occur with color Doppler US, may be reduced by decreasing the gain or changing the angle of insonation.

Multipath artifacts result from additional reflections of a portion of the beam on the path to or from a primary reflector. For example, the transmitted beam may encounter a primary reflector, reflect back but off axis, and then reflect off a second adjacent reflector along the path back to the transducer (Fig 10c). This results in the object appearing to be slightly deeper than it actually is because of an increased path length. Compared with mirror image and reverberation artifacts, these artifacts are usually relatively minor and contribute to general image degradation rather than appearing as discrete identifiable artifacts (14).

### Refraction

Refraction is a phenomenon whereby a wave changes direction at an interface between mediums having different speeds of sound. This change in direction is predictable and is governed by the Snell law, which states that  $\sin x/\sin y = V_x/V_y$ , where  $x$  is the angle of incidence,  $y$  is the angle of refraction, and  $V_x$  and  $V_y$  represent the local speeds of sound propagation in the mediums at the interface between the two. If the incident beam is perpendicular to the boundary, no refraction will occur. As the angle of incidence increases and as the difference in the speeds of sound is greater,

**Figure 11.** Refraction artifacts. (a) Diagram shows misregistration due to refraction, whereby the path of the beam is altered as it obliquely encounters an interface between mediums with different speeds of sound. The position of a target (black circle) deep to the interface will be altered (dotted circle). (b) Diagram demonstrates the concept of ghosting in the abdomen, whereby an object may appear in duplicate or triplicate due to refraction. At paramedian beam positions, refraction superficially (gray arrows) causes the same object to be imaged but misregistered at these positions (dotted circles). Centrally, no refraction occurs and the true position (black circle) of the object is obtained. (c) Transverse US image of the liver in a 29-year-old woman shows ghosting artifact of the aorta, which appears in duplicate (arrows) deep to the rectus abdominis musculature (\*). (d) Diagram shows edge shadowing (defocusing) at the edge of a cystic structure with a different speed of sound than that of the surrounding medium. Refraction is greatest at the edges, resulting in shadowing due to the decreased beam intensity to deeper tissues. (e) Transverse US image of a complicated cyst in the breast of a 51-year-old woman shows edge shadowing (arrows) at the periphery.



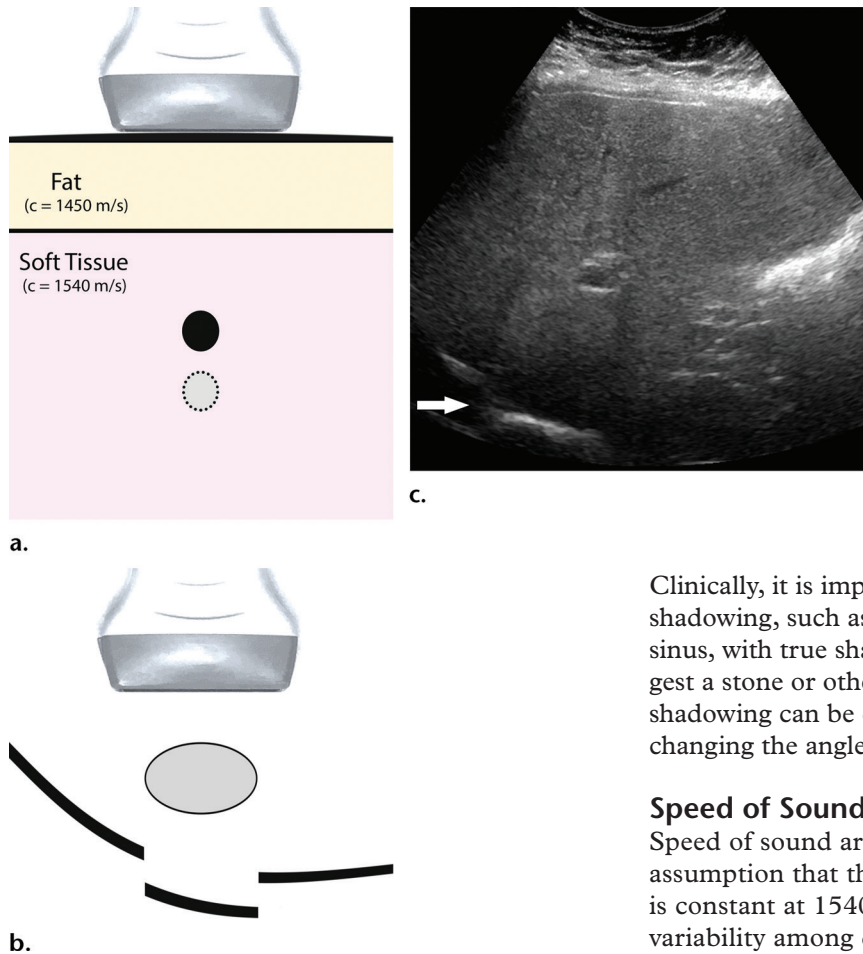
more refraction will occur. Therefore, refraction is often most pronounced at highly oblique interfaces, such as the lateral aspect of a curved surface, and with interfaces between substances such as fat and muscle with disparate speeds of sound. This basic principle underlies misregistration, ghosting, and edge-shadowing artifacts.

Misregistration is a basic application of refraction, where the actual location of an object is altered by refraction of the beam at an interface superficial to it (Fig 11a). US assumes the beam travels along a straight line and will reconstruct the image without accounting for any refraction that is occurring. Therefore, the edges of structures and the relationships of objects may actually be slightly

different than they appear. A classic visual example of misregistration is the displaced appearance of a pencil when it is submerged in a glass of water.

Ghosting (duplication) is a refractive artifact where a deep structure may appear in duplicate or triplicate by refraction of the beam superficial to it. Ghosting is most often observed when imaging pelvic structures through the rectus abdominis and abdominal wall fat. Because of the differences in the speed of sound between the tissues and the oblique angle of the incident beam, the rectus abdominis acts as a lens, which results in the interrogation of a deep structure by two or three separate beams (Fig 11b, 11c). The reflected echoes are refracted again by the rectus

**Figure 12.** Speed of sound artifacts. (a) Diagram shows a thick layer of fat superficial to the underlying tissue. Since the actual speed of sound in the fat (1450 m/sec) is less than what is assumed (1540 m/sec) to calculate depth, the longer time for both transmitted and returning echoes to travel through this region results in a misregistration of all underlying targets, which appear deeper (dotted circle) than the true position (black circle).  $c$  = speed of sound. (b) Diagram shows boundary distortion artifact occurring deep to a structure with a lower speed of sound than the surrounding tissue. (c) Longitudinal US image of the liver in a 54-year-old man with focal hepatic steatosis shows a boundary distortion artifact (arrow) of the liver edge due to variability in overlying fatty infiltration.



abdominis and appear to return to the transducer from different locations. As US reconstructs the image by assuming that received echoes travel in a straight line, the result is duplication of an underlying structure, such as a double gestational sac, aorta, or spinal cord.

Edge shadowing (defocusing) is a refractive artifact that occurs at the edge of a large curved boundary with a different speed of sound than that of the surrounding tissues. This is often observed at the lateral edges of a structure such as a cyst or soft-tissue mass and appears as hypoechoic parallel lines projecting distal to the edges of the structure (Fig 11d, 11e). As the angle of the boundary increases, the ultrasound beam both reflects and refracts off the surface. The intensity of the beam reaching the tissue immediately distal to the edge of the curve is therefore decreased and appears as a shadow.

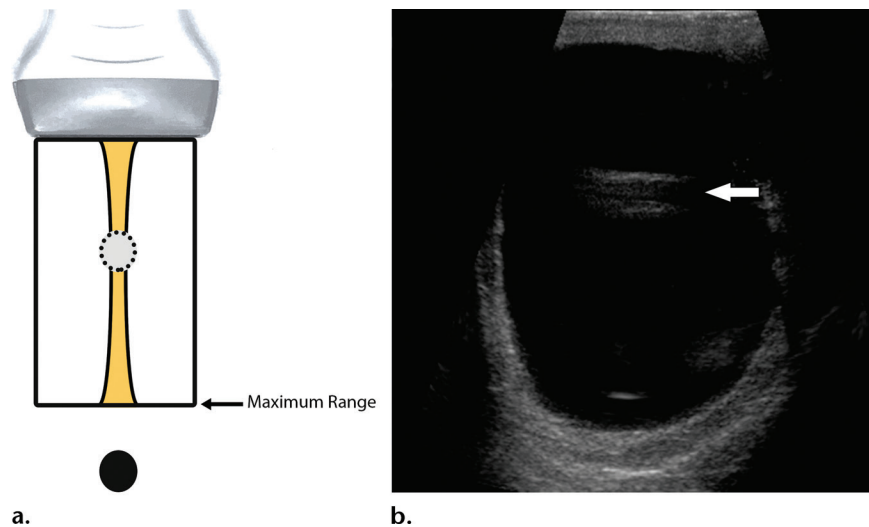
Clinically, it is important not to confuse edge shadowing, such as that from a vessel in the renal sinus, with true shadowing, which would suggest a stone or other highly reflective focus. Edge shadowing can be decreased or eliminated by changing the angle of insonation.

### Speed of Sound Artifacts

Speed of sound artifacts occur because of the assumption that the propagation speed of sound is constant at 1540 m/sec, when in fact there is variability among different tissues. In creating the US image, the depth of an echo is calculated from the time delay between transmitting a pulse and receiving an echo, with an assumption of a constant sound speed of 1540 m/sec in soft tissue. If the speed of sound in the tissue is actually less, such as in fat (1450 m/sec), it will take relatively longer for the echo to be received, and it will be displayed as if it originated from a more distant target. Conversely, if the speed of sound is greater, the echo will appear closer. This concept results in several variations of related artifacts.

Boundary distortion (speed displacement artifact) occurs when a portion of the beam encounters a region of differential velocity superficial to a smooth interface, giving rise to a distorted appearance of the interface (Fig 12). This is commonly encountered when imaging the liver through a region of focal fat, where the portion of the beam traversing the fat takes longer to return to the transducer. As a result, the diaphragm

**Figure 13.** Range ambiguity artifact. (a) Diagram shows that if an echo from a distant structure is received after the next pulse is transmitted (ie, beyond the pulse repetition period), the depth will be calculated from the second pulse and the target will be registered as closer than it actually is. (b) Transverse US image of the scrotum in a 29-year-old man with a large hydrocele shows artifactual echoes (arrow) in the middle of the fluid due to late-returning echoes from the posterior wall.



appears deeper in that portion than it actually is. Boundary distortion is also the underlying mechanism of bayonet artifact, whereby a needle has a discontinuous or bent appearance when it is traversing or is deep to a lesion with a different speed of sound than that of the surrounding tissues. In general, imaging through tissues that differ from the assumed 1540 m/sec gives rise to misregistration of targets. For example, when imaging targets through a uniform layer of fat, such as a large amount of subcutaneous fat or breast tissue, boundary distortion will not occur but the depth of all targets will be overestimated. Similarly, errors in size in the axial dimension occur when imaging an object composed of tissues in which the speeds of sound differ from 1540 m/sec. For example, because the speed of sound in fat is approximately 5% less than that in soft tissue, a 5-cm dermoid will be falsely measured as being 5.25 cm. Whereas small differences in size or location are not often important in image interpretation, they may be very relevant in applications such as US-guided radiation therapy, where small differences in size or location are critical (15).

Differences in the velocities of tissues also give rise to the important concept of phase aberration. Array transducers are precisely calibrated with electronic delays on the central elements so that transmit pulses from all elements arrive at a focus at the same time, assuming a constant speed of sound of 1540 m/sec. Variations in the speed of sound of real tissues result in distortion of the wavefront and deterioration of lateral resolution, particularly at increased depths and with higher frequencies (2). In Figure 2b, a broader beam width, which causes more lateral blurring of the point target, is observed when the speed of sound assumption used by the US unit (1540 m/sec) differs from the actual speed of sound in the phantom material (1450 m/sec). When the

assumed speed of sound value used by the US unit is adjusted to match that of the phantom material, improved lateral resolution is achieved, as shown in Figure 2c. Modern US units allow manual speed of sound value correction, which can be particularly useful at breast imaging to improve lateral resolution.

### Range Ambiguity

Range ambiguity artifact results when the assumption that all returning echoes are generated by the most recently transmitted pulse is violated. Depth is assigned based on the time interval between the transmitted pulse and the received echo. If a distant echo of a deep structure from an initial pulse is received after a second pulse is generated, the time delay will be counted from the second pulse emission instead of the first pulse emission. Therefore, the distance will be misregistered as closer to the transducer than it actually is (Fig 13). Range ambiguity artifact can be improved by decreasing the pulse repetition frequency, thereby increasing the pulse repetition period and giving more time for listening for echoes.

### Attenuation Artifacts

As an ultrasound wave travels through tissue, its amplitude reduces with increasing distance, which is called attenuation. Although absorption is usually the dominant mechanism to cause attenuation, acoustic reflection, scattering, and divergence of the beam also contribute to attenuation. Tissues absorb acoustic energy and convert it to heat in a process highly dependent on tissue composition and structure (2). Both absorption and acoustic scattering are frequency dependent, so that the overall attenuation increases nearly linearly with increasing frequency in most tissues, with attenuation coefficients expressed as decibels per centimeter per megahertz.

Hence the trade-off for improved spatial resolution through higher frequency beams is increased attenuation and decreased penetration of deeper structures. Attenuation coefficients vary significantly between different tissues, including 0.02 dB/cm/MHz in water, 0.4 dB/cm/MHz in liver, and 20 dB/cm/MHz in bone (2). To compensate for the expected increased attenuation with depth, US units use TGC to adjust the amplification of the receiver as a function of echo arrival time (deeper structures are amplified more). A baseline first-order compensation is employed that assumes a uniform attenuation in soft tissues, which can be adjusted by the operator through slide controls on the unit. It is the deviation of the true tissue attenuation from the assumed TGC that results in the structure of the image and also in attenuation artifacts.

### Increased Through Transmission

Increased through transmission (posterior acoustic enhancement) refers to the increased intensity of echoes relative to surrounding tissues occurring distal to a low-attenuating structure. This can be thought of as an overcompensation of the TGC, with distal tissues appearing echogenic (Fig 14). Increased through transmission is helpful in distinguishing cystic from solid structures, but it must be remembered that a homogeneous solid lesion with a lower attenuation than the adjacent tissues will also exhibit increased through transmission.

### Acoustic Shadowing

Acoustic shadowing refers to the reduction in echo strength distal to a highly attenuating or reflective object. It can be thought of as a failure of the TGC to adequately amplify these distal echoes and appears as a dark band deep to the object (Fig 14). Shadowing can be very useful clinically, is often seen with calcifications, bone, and gas, and appears as clean, partial, or dirty shadowing. Clean shadowing commonly occurs distal to larger calculi and bone and appears as a dark anechoic band. In this case, most of the energy is absorbed and is not available for secondary reflections. Similarly, rough surfaces with small radii of curvature will more likely produce clean shadowing due to scattering and loss of beam coherence (16). Echogenic distal common bile duct stones and renal stones can be difficult to identify owing to adjacent echogenic structures, and therefore the presence of shadowing is critical for their recognition. Additionally, shadowing is important for differentiating mobile shadowing gallstones from nonmobile nonshadowing gallbladder polyps and mobile nonshadowing sludge balls. Partial shadowing appears as a hypoechoic band and

occurs distal to highly attenuating soft tissues, such as fat, or small stones, where the cross section of the beam is greater than the diameter of the stone. In this case, adjusting the focal zone to the depth of the stone is important to minimize section thickness and maximize shadowing. Dirty shadowing is commonly seen distal to a highly reflecting surface such as gas, whereby multiple secondary reflections produce low-level echoes that appear within the shadow, similar to ring-down artifact. To use certain image artifacts, such as shadowing behind a stone, for diagnosis, one should understand the conditions producing the artifacts. Inappropriate focal zone placement, excessive beam widths, and spatial compounding will decrease shadowing (Fig 15). As some degree of spatial compounding is built into many imaging protocols on modern US units, it is important to turn this off when imaging stones. Conversely, imaging with increased-frequency probes and using THI will increase shadowing (17,18).

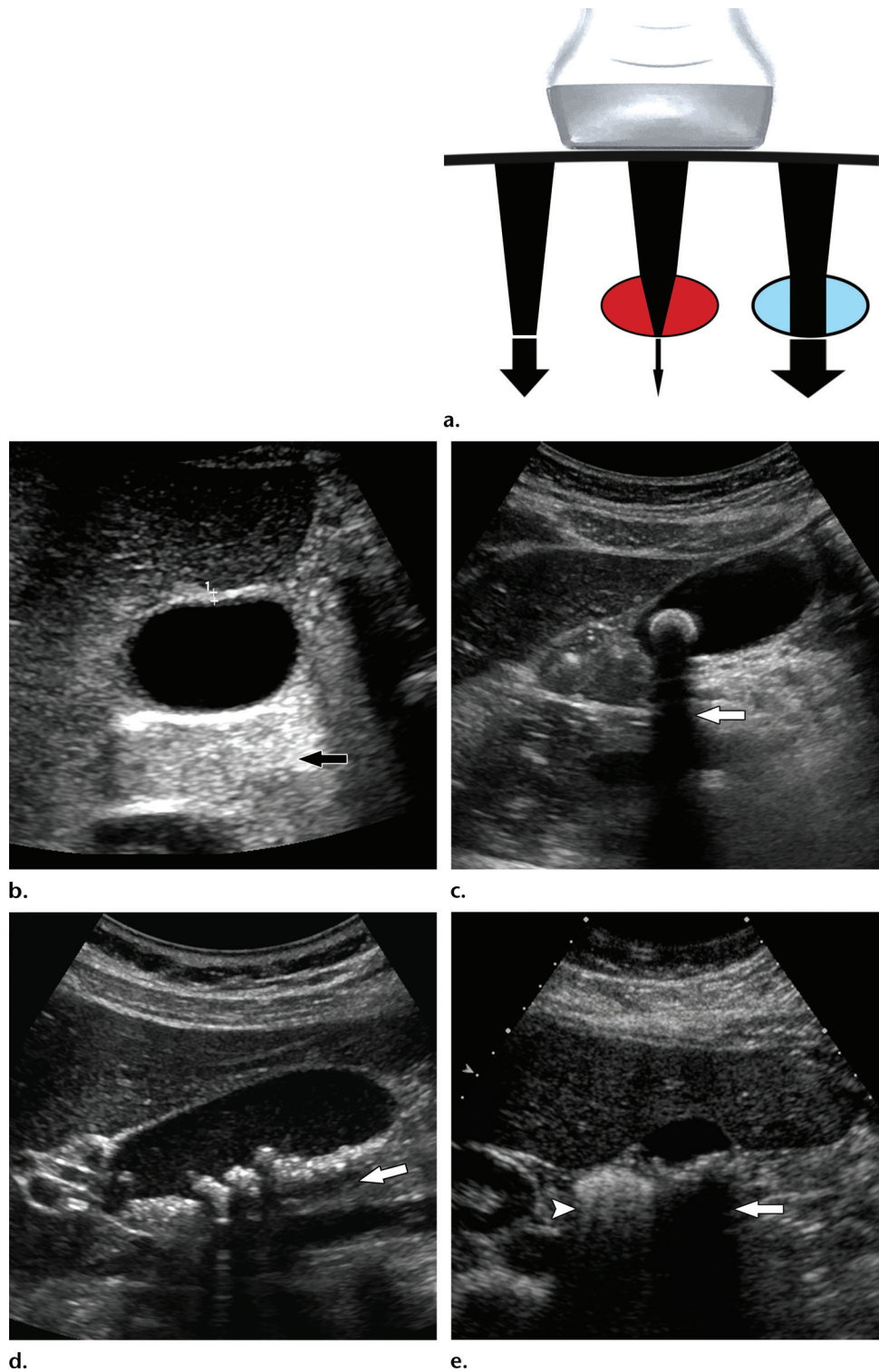
### Conclusion

Many artifacts result from violations of the underlying assumptions made in constructing the image and can be explained by underlying physical principles. Artifacts are widespread in US, and although some are generally unwanted, others reveal valuable information related to the structure and composition of the tissue being imaged. Optimal US technique is needed to diminish artifacts that may interfere with image interpretation. In addition, radiologists should be able to use artifacts on US images to improve the specificity of diagnosis.


**Acknowledgments.**—The authors gratefully acknowledge Kate A. Feinstein, MD, and Carolyn Donaldson, MD, for contributing images, as well as the University of Chicago Medicine sonographers for their assistance. We would also like to thank Glenn Gerber, MD, for providing kidney stones for use in phantom experiments.

### References

1. Zagzebski JA. Essentials of ultrasound physics. St Louis, Mo: Mosby, 1996.
2. Hoskins PR, Martin K, Thrush A. Diagnostic ultrasound: physics and equipment. 2nd ed. Cambridge, England: Cambridge, 2010.
3. Szabo T. Diagnostic ultrasound imaging: inside out. Oxford, England: Elsevier, 2004.
4. Middleton WD, Siegel MJ, Dahiya N. Ultrasound artifacts. In: Siegel MJ, ed. Pediatric sonography. 4th ed. Philadelphia, Pa: Lippincott Williams & Wilkins, 2011; 21–42.
5. Gill R. The physics and technology of diagnostic ultrasound: a practitioner's guide. Sydney, Australia: High Frequency Publishing, 2012.
6. Barthez PY, Léveillé R, Scrivani PV. Side lobes and grating lobes artifacts in ultrasound imaging. *Vet Radiol Ultrasound* 1997;38(5):387–393.
7. Bushberg JT, Seibert AJ, Leidholdt EM Jr, Boone JM. Ultrasound. In: The essential physics of medical imaging. 3rd ed. Philadelphia, Pa: Lippincott Williams & Wilkins, 2012;500–576.



**Figure 14.** Increased through transmission (posterior acoustic enhancement) and acoustic shadowing. (a) Diagram shows the generation of increased through transmission and shadowing. Attenuation is assumed to be uniform, and a baseline TGC is used to amplify echoes from deeper tissues. If a portion of tissue is less attenuating (blue ellipse), the beam distal to this region will be more intense and the tissue deeper will appear relatively bright owing to overcompensation from the TGC. However, if a portion of tissue is more attenuating or reflective (red ellipse), the beam distal to this region will be less intense and the tissue deeper will appear relatively dark. (b) Transverse US image of a normal gallbladder in a 24-year-old woman shows increased through transmission (arrow) due to decreased attenuation of echoes passing through the fluid of the gallbladder lumen. (c) Transverse US image of the gallbladder in a 41-year-old woman with cholelithiasis shows clean shadowing (arrow) deep to a large stone. (d) Longitudinal US image in a 64-year-old man with cholelithiasis shows a gallbladder filled with multiple small stones. The shadows (arrow) of smaller stones cannot be resolved. (e) Transverse US image of the gallbladder in a 47-year-old woman with cholelithiasis shows dirty shadowing (arrowhead), resulting from an air-filled bowel loop, next to clean shadowing (arrow) from a gallbladder filled with stones.



**Figure 15.** US images of a phantom containing a kidney stone demonstrate a shadow (arrow). The shadow at spatial compounding (**b**) is wider and less intense than at standard fundamental US (**a**).

8. Danse EM, Van Beers BE, Gilles A, Jacquet L. Sonographic detection of intestinal pneumatosis. *Eur J Ultrasound* 2000;11(3):201–203.
9. Bhargava P, Parisi M. Gastric pneumatosis and portal venous gas: benign findings in hypertrophic pyloric stenosis. *Pediatr Radiol* 2009;39(4):413.
10. Anvari A, Forsberg F, Samir AE. A primer on the physical principles of tissue harmonic imaging. *RadioGraphics* 2015;35(7):1955–1964.
11. Avruch L, Cooperberg PL. The ring-down artifact. *J Ultrasound Med* 1985;4(1):21–28.
12. Soldati G, Copetti R, Sher S. Sonographic interstitial syndrome: the sound of lung water. *J Ultrasound Med* 2009;28(2):163–174.
13. Heng HG, Widmer WR. Appearance of common ultrasound artifacts in conventional vs. spatial compound imaging. *Vet Radiol Ultrasound* 2010;51(6):621–627.
14. Kremkau FW, Taylor KJ. Artifacts in ultrasound imaging. *J Ultrasound Med* 1986;5(4):227–237.
15. Fontanarosa D, van der Meer S, Bamber J, Harris E, O'Shea T, Verhaegen F. Review of ultrasound image guidance in external beam radiotherapy: I. Treatment planning and interfraction motion management. *Phys Med Biol* 2015;60(3):R77–R114.
16. Rubin JM, Adler RS, Bude RO, Fowlkes JB, Carson PL. Clean and dirty shadowing at US: a reappraisal. *Radiology* 1991;181(1):231–236.
17. Ortega D, Burns PN, Hope Simpson D, Wilson SR. Tissue harmonic imaging: is it a benefit for bile duct sonography? *AJR Am J Roentgenol* 2001;176(3):653–659.
18. Szopinski KT, Pajk AM, Wysocki M, Amy D, Szopinska M, Jakubowski W. Tissue harmonic imaging: utility in breast sonography. *J Ultrasound Med* 2003;22(5):479–487; quiz 488–489.